

Photo collections

- Sheep
- Goat
- Camel

Animal Medicine Department

Faculty of Veterinary Medicine

Benha University

Prof Dr. Mohamed Ghanem

Part 2

Vit D def

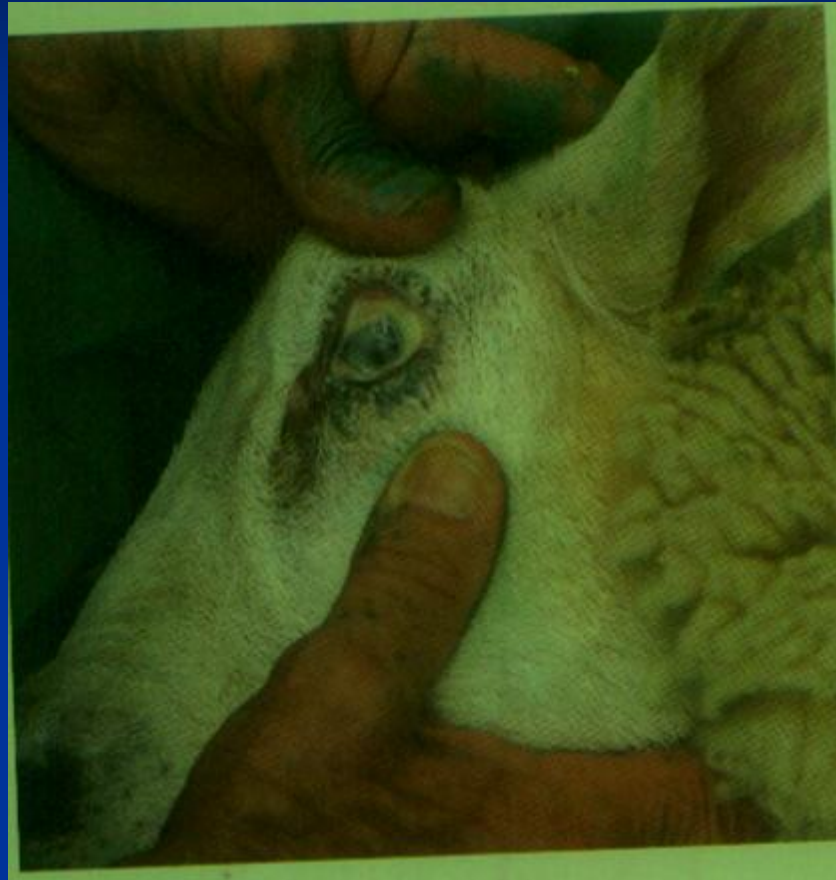

Arched back- stiffness in hind limb

Parakeratosis (zinc deficiency)



Skin appears as raw and red



cloudiness of eye –vit A deficiency

Vit. E and/or selenium deficiency

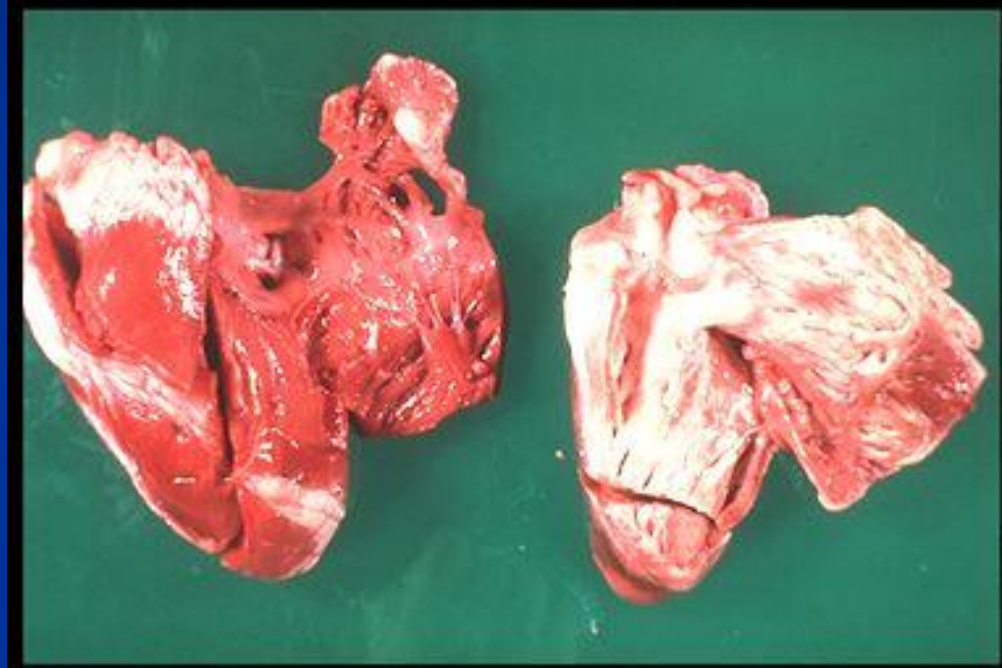


Vit. E and selenium Deficiency



notice enlarged rear quarters, altered stance, and shifting of weight to the front legs

Vit. E and selenium Deficiency

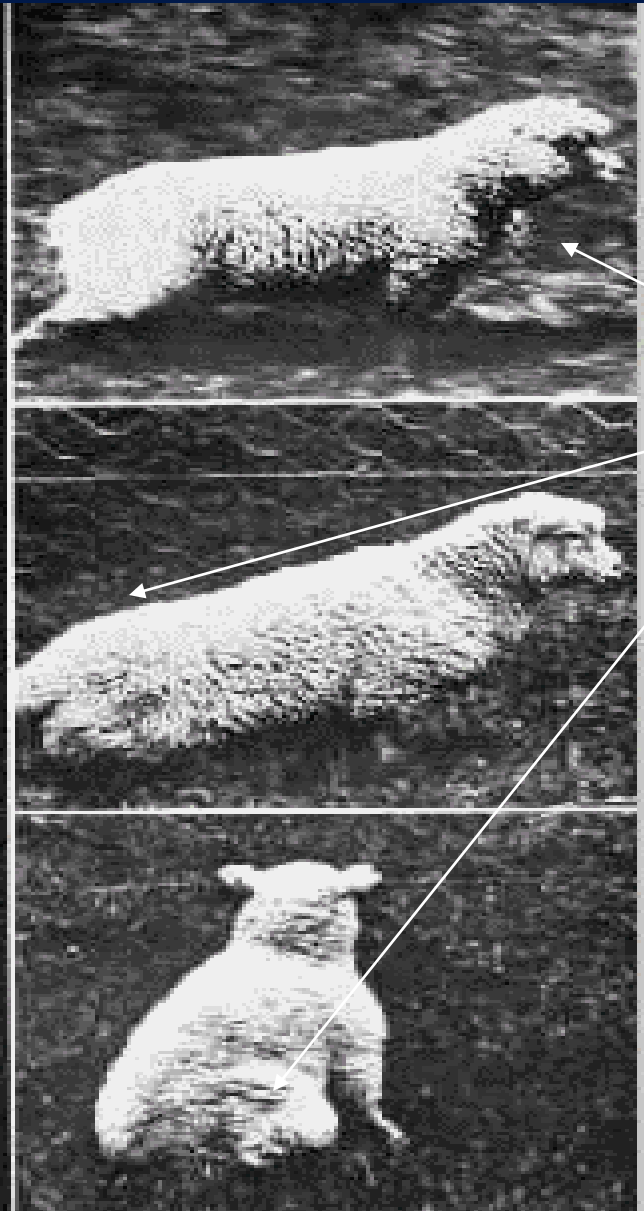
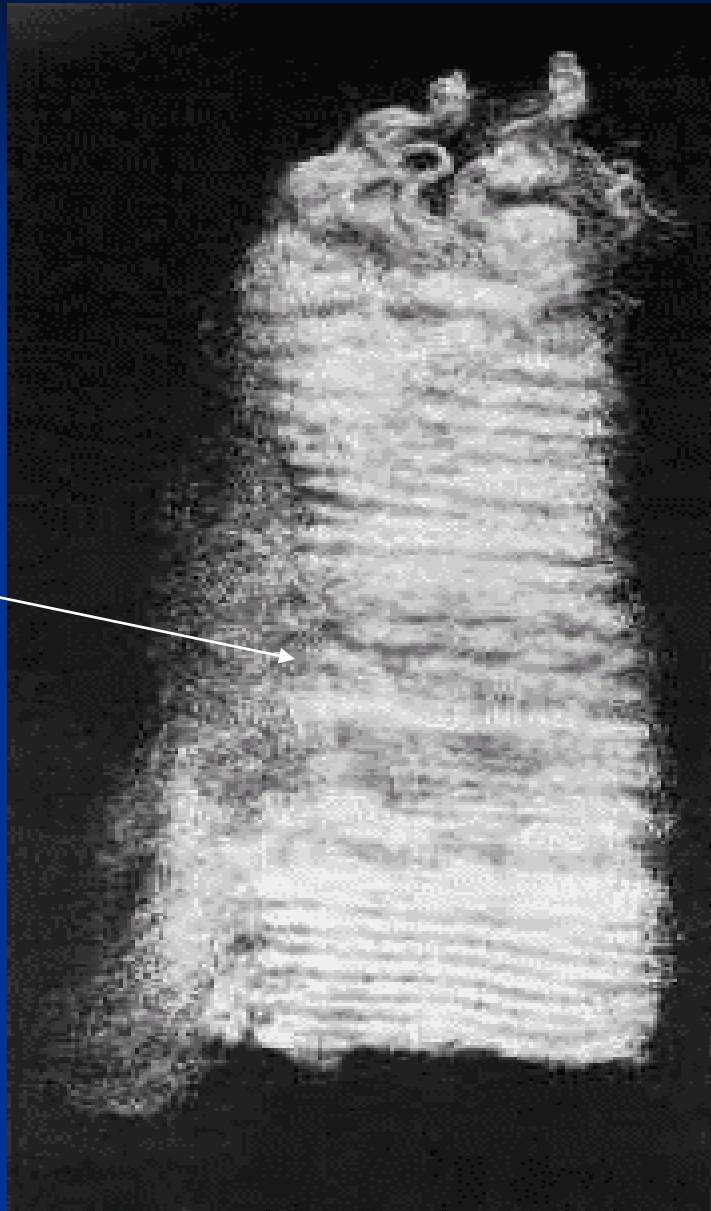


White muscle streaks


Enzootic ataxia –copper deficiency



Steely wool



Enzootic ataxia



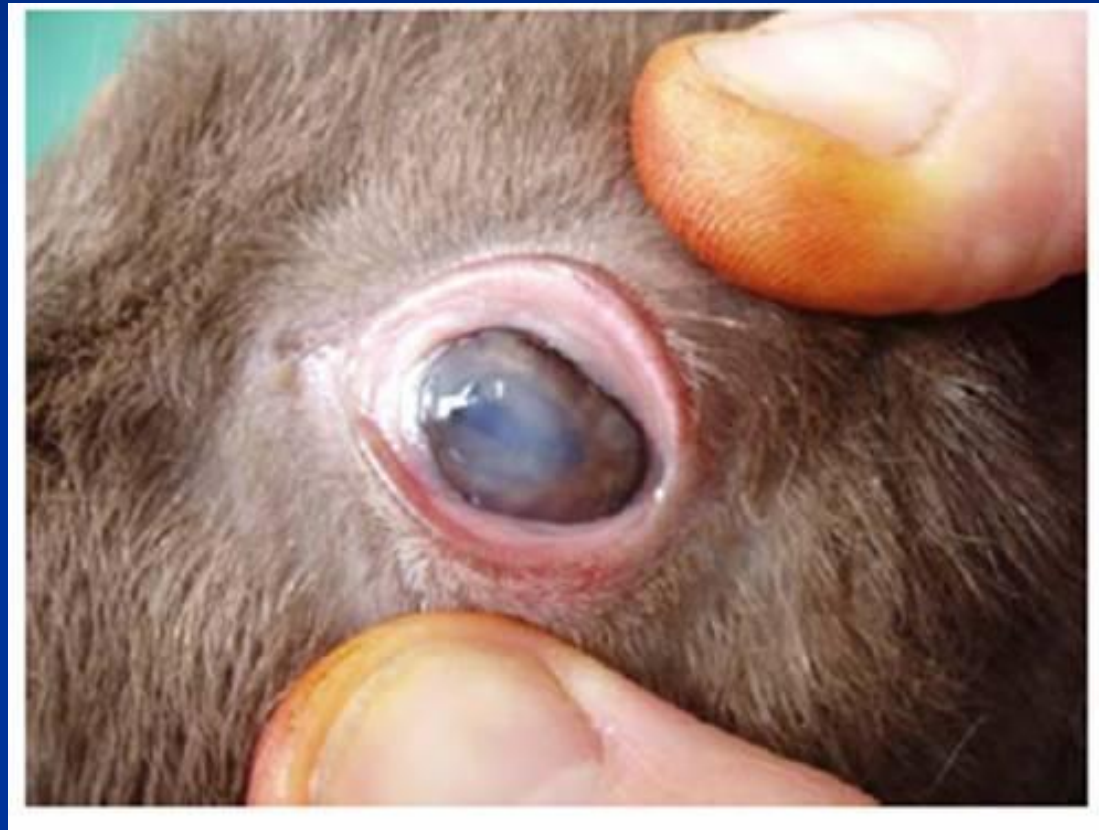
Normal crimp

Loss of crimp

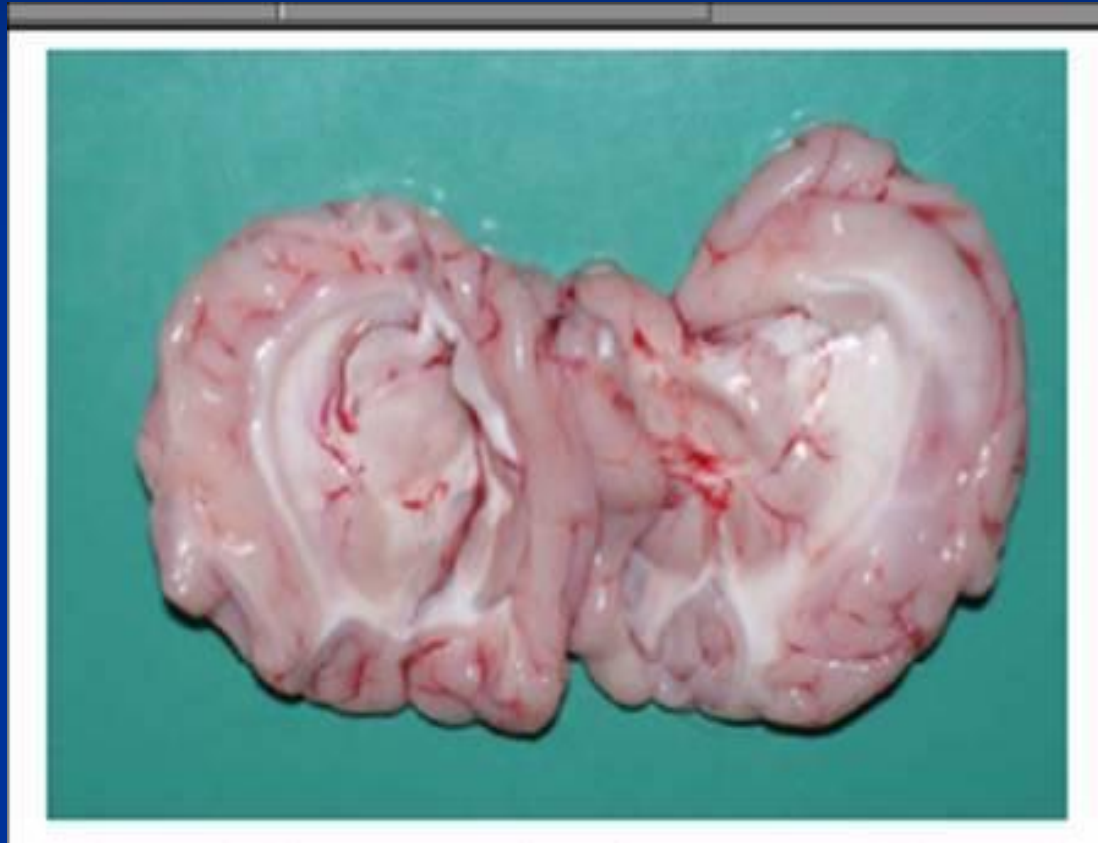Copper deficiency in a goat – abnormal color of hair



Copper deficiency – depigmentation of hair around eye



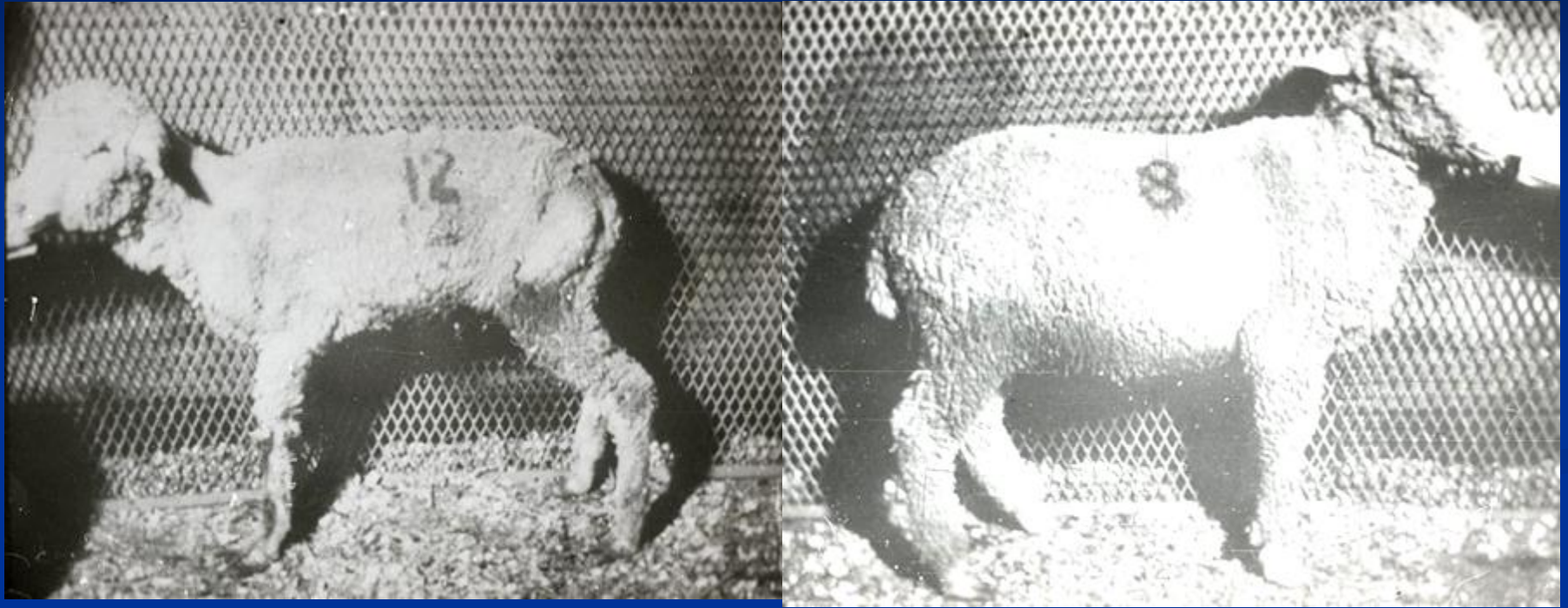
Necrosis of white matter of right cerebral hemisphere – copper deficiency



Sway back disease in a lamb hind limb paresis



Cobalt deficiency



Cobalt-deficient lamb (pining)

Cobalt adequate lamb

Cobalt deficiency - emaciation

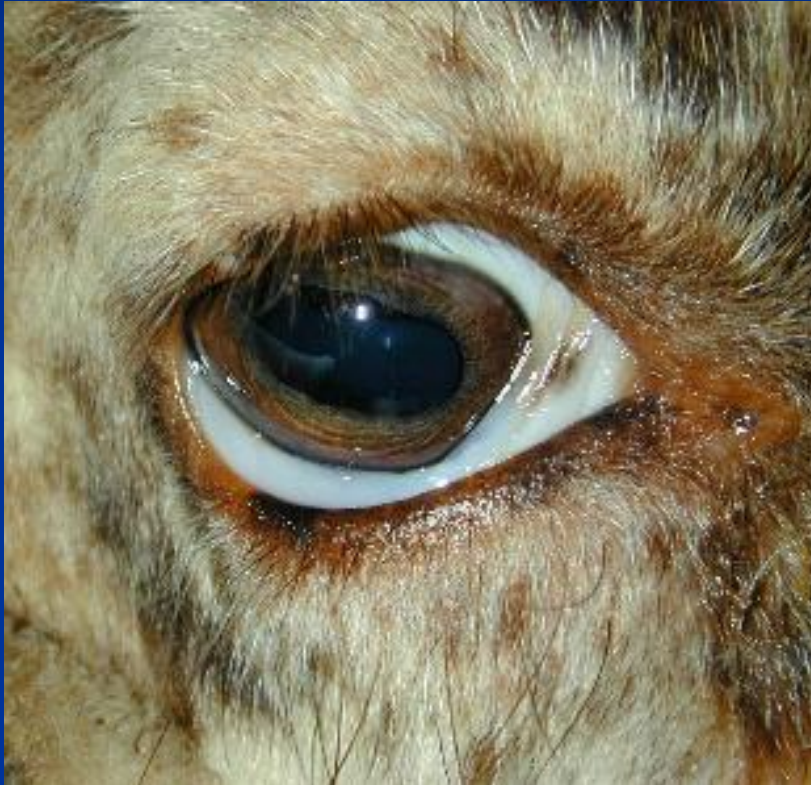

Anemia (copper and iron deficiency)



Pale gum

Paleness of conjunctival mm

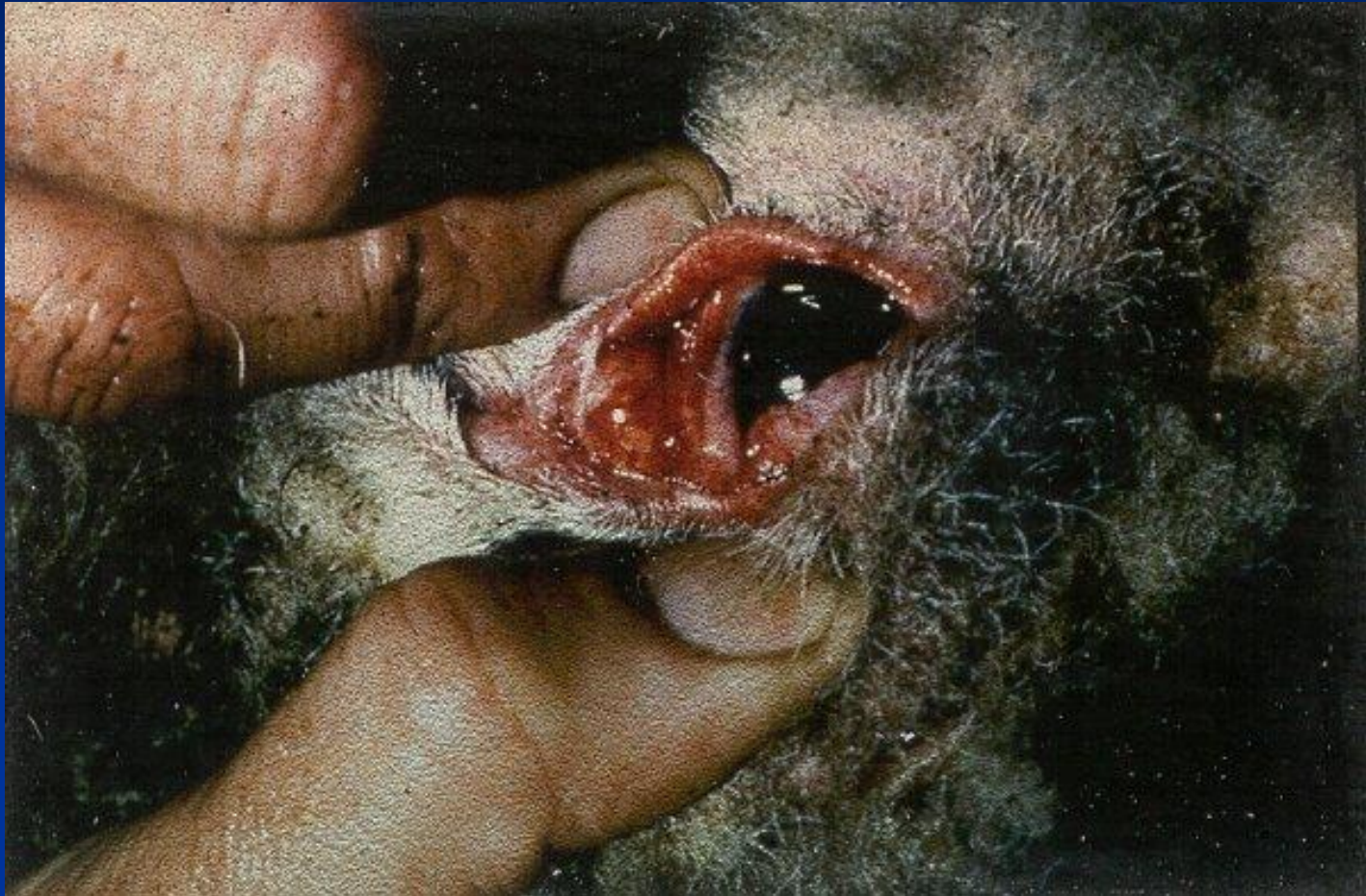

Pale MM




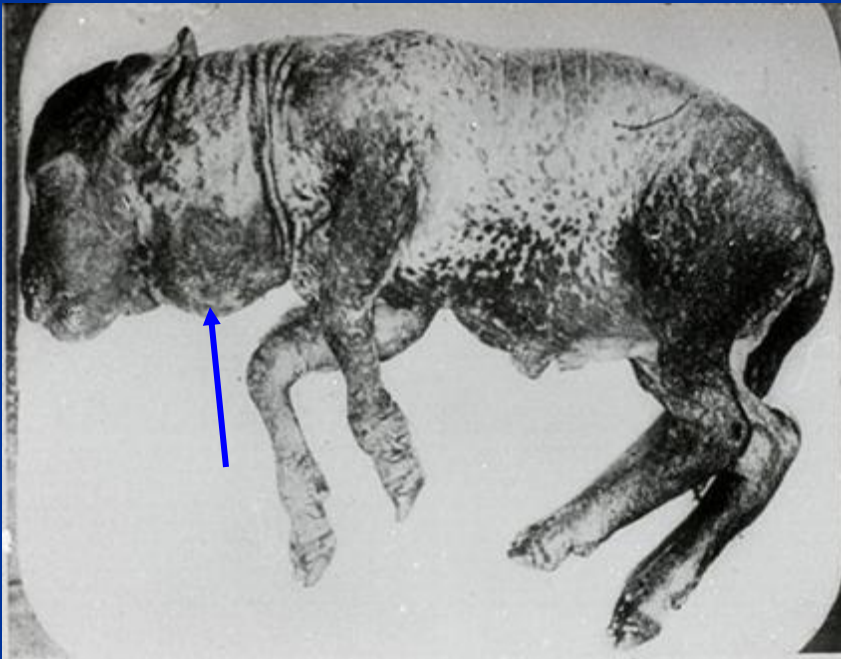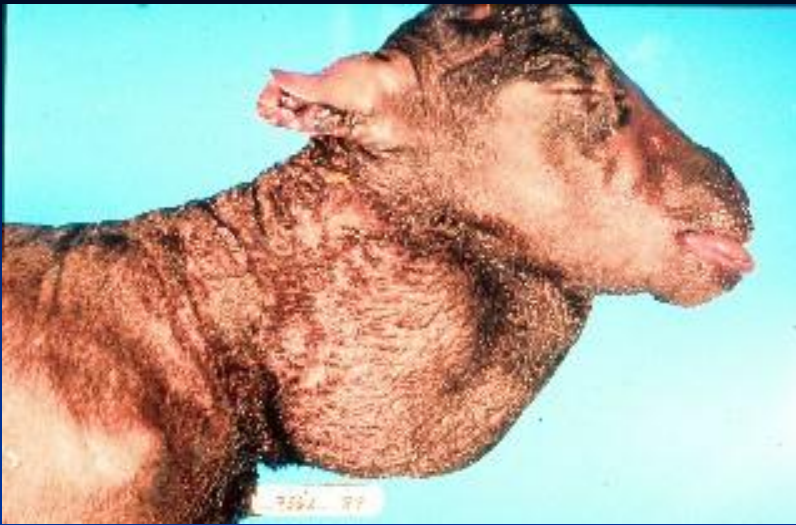
Normal

Congested ocular mm



Congested conjunctiva

Iodine deficiency - Goiter




Sheep with goiter in a region of iodine deficiency
Овца с зобом в регионе с йодной недостаточностью.

Alopecia due to iodine deficiency in a kid



Polioencephalomalacia in goat



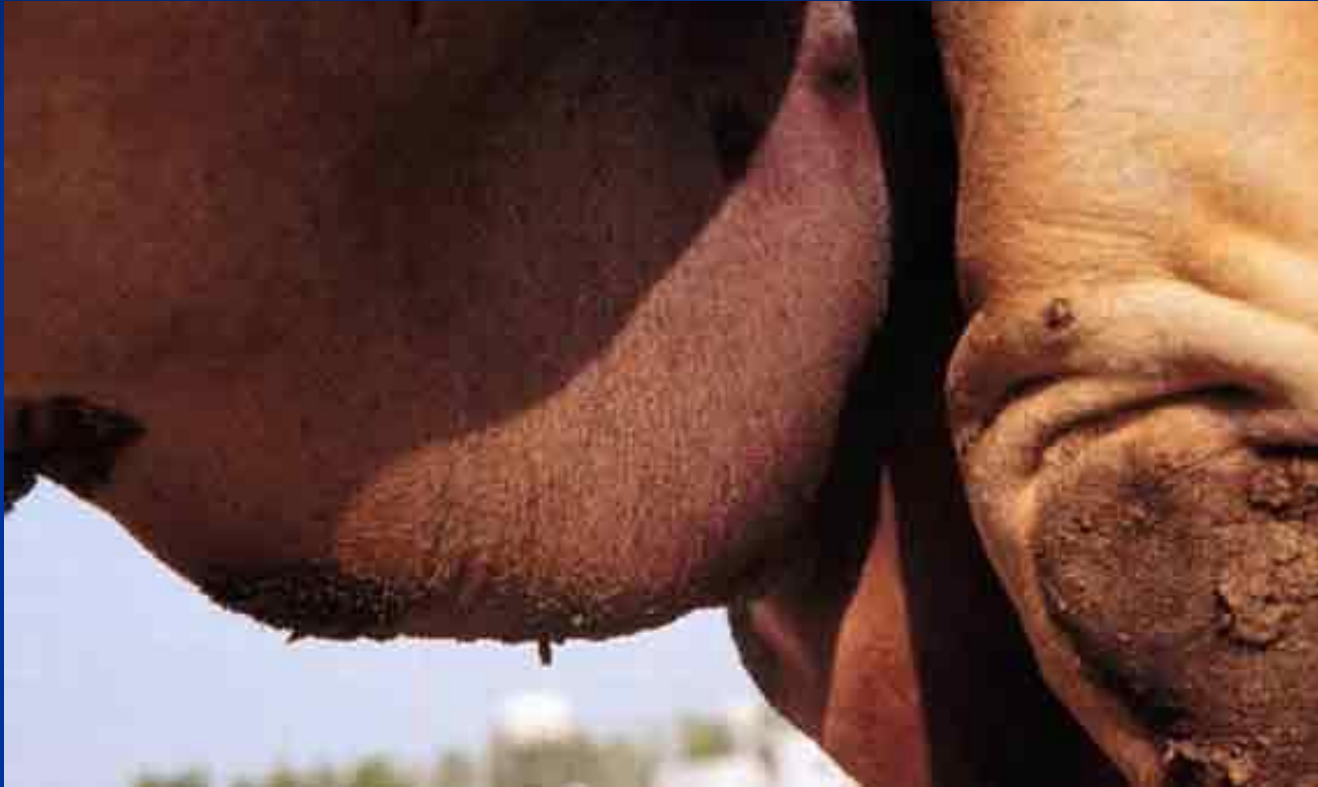Polioencephalomalacia in sheep



Encephalopathy due to prion (aggressiveness and abnormal gait)



Urolithiasis and ruptured urethra (cattle)



Preputial swelling in a male dromedary - urolithiasis with urethral rupture

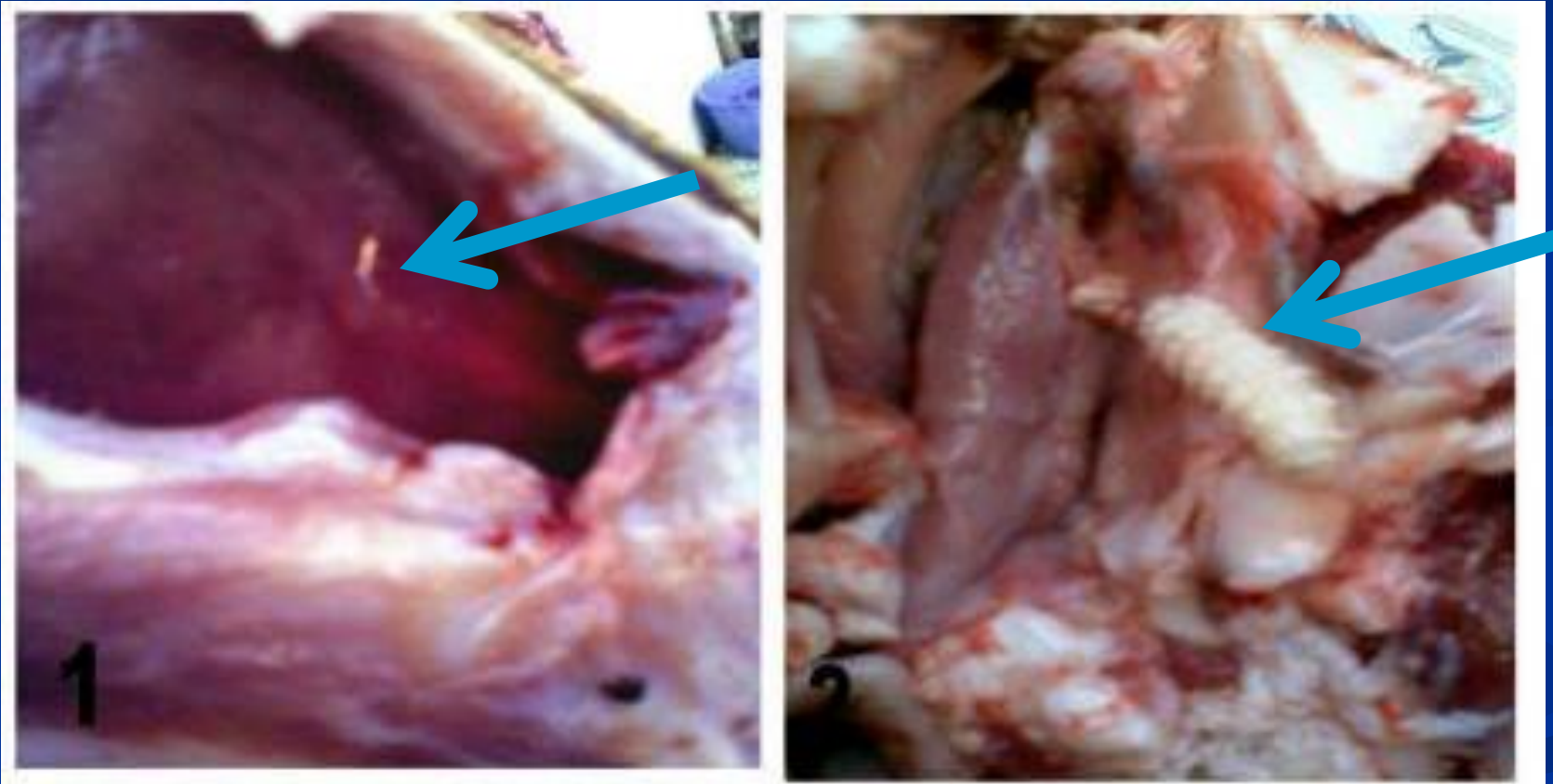
Cephalopina titillator larva



Nasal discharge in a camel



Cephalopina titillator in camel



Cephalopina titillator in camel



Parasitic dermatitis



Mycotic dermatitis (ring worm)

